








Open double-button technique is superior to hook plate in the treatment of acute Rockwood Type III/V acromioclavicular dislocations

 Furkan Yapici, M.D.,¹  Hanifi Ucpunar, M.D.,¹  Volkan Gur, M.D.,¹  Ahmet Sevcen, M.D.,²
 Yusuf Onur Kizilay, M.D.,³  Resit Karakose, M.D.,¹  Yalkin Camurcu, M.D.³

¹Department of Orthopedics and Traumatology, Erzincan University Faculty of Medicine, Erzincan-Turkey

²Department of Orthopedics and Traumatology, MS Baltalimanı Bone and Joint Diseases Training and Research Hospital, İstanbul-Turkey

³Department of Orthopedics and Traumatology, Atlas University Faculty of Medicine, İstanbul-Turkey

ABSTRACT

BACKGROUND: The aim of this study is to compare open double-button (DB) and hook plate (HP) techniques in the treatment of acromioclavicular joint dislocation (ACJD) in terms of clinical and radiological outcomes and to determine which method is superior.

METHODS: This retrospective comparative study included patients with ACJDs (Rockwood Type III/V) who were treated with one of these implants (22 patients with HP, 21 patients with DB) between June 2014 and February 2018.

RESULTS: A total of 43 patients (39 men and 4 women) with a mean age of 41.8 ± 17.4 years have participated in this study. The mean follow-up time was 20.6 ± 7.5 months. Mean times of fluoroscopy, operation, and return to work were shorter in the DB group. Complication rates were 23.8% and 54.6%, reoperation rates (including mandatory implant removals [IR]) were 4.8% and 77.3%, mean constant scores were 92.1 ± 3.4 and 88.3 ± 4.2 , and mean Visual Analog Scale scores were 0.8 ± 1.0 and 1.5 ± 1.0 for the DB and HP groups, respectively. IR was the main reason for reoperations in the HP group, whereas the DB group's only reoperation was caused by a coracoid cutout (due to coracoid tunnel malposition) leading to redislocation. AC joint arthritis (36.4%) and subacromial osteolysis (31.9%) were commonly encountered in the HP group. The most frequent complication of the DB group was malreduction (initial undercorrection) (9.6%).

CONCLUSION: DB was superior to HP in functional outcome, post-operative pain, complication and reoperation rates, operation and fluoroscopy times, and time to return to work. Besides, reoperation (for IR) was needed in most of the HP patients. Therefore, the open DB technique should be preferential to the HP procedure.

Keywords: Acromioclavicular joint dislocation; double-button; endobutton; hook plate; lift loop system; post-operative complications; Rockwood classification; suture-button; tightrope; treatment outcome.

INTRODUCTION

Acromioclavicular joint dislocation (ACJD) occurs with a direct blow to the acromion when the shoulder is adducted or an indirect trauma to the elevated arm, resulting in the injury of AC, coracoclavicular (CC) ligaments, and deltotracheal fascia.^[1-3] It accounts for 9% of all shoulder injuries, 50% of sports-related shoulder injuries, and mostly occurs in men (Men/Women: 5/1) in the second decade.^[4-7]

Rockwood classification is used for ACJDs based on the magnitude and direction of the dislocation.^[8] Rockwood Type I-II injuries are treated conservatively,^[9] whereas high-grade injuries (Type IV-VI) are treated surgically.^[10] The treatment of Type III ACJD is determined by the patient's preferences and demands. Thus, it should be individualized based on activity level, functional impairment, occupational needs, type of sport, level of play, and esthetic preferences of the patient.^[11] Athletes, active laborers, patients who had frequent overhead

Cite this article as: Yapici F, Ucpunar H, Gur V, Sevcen A, Kizilay YO, Karakose R, et al. Open double-button technique is superior to hook plate in the treatment of acute Rockwood Type III/V acromioclavicular dislocations. *Ulus Travma Acil Cerrahi Derg* 2022;28:839-848.

Address for correspondence: Furkan Yapici, M.D.

Erzincan Binali Yıldırım Üniversitesi Tıp Fakültesi, Ortopedi ve Travmatoloji Anabilim Dalı, Erzincan, Turkey

Tel: +90 446 - 212 22 22 E-mail: furkanyapici@hotmail.com

Ulus Travma Acil Cerrahi Derg 2022;28(6):839-848 DOI: 10.14744/tjtes.2021.45985 Submitted: 21.12.2020 Accepted: 12.05.2021

Copyright 2022 Turkish Association of Trauma and Emergency Surgery



activities in their daily lives, and young active patients with high demands should be treated surgically.

There are various types of AC or CC augmentations/fixations used for the surgical treatment of ACJD: (1) AC fixation with K wires (Phemister technique)/threaded pins/tension band wiring, (2) AC fixation with hook plate (HP), (3) CC fixation with a screw (Bosworth technique), (4) coracoacromial (CA) ligament transfer to the distal end of the clavicle with the resection of the lateral clavicle (Weaver-Dunn procedure), and (5) CC loop suspensory fixations (LSF) (metallic cables/cerclages, autologous/artificial ligaments, absorbable PDS [polydioxanone sulfate] slings and double-buttons [DBs]).^[11-16] Although the use of K wires/threaded pins is not recommended due to pin migration/breakage, pin site infection, and recurrent instability after removal,^[17-19] the ideal surgery for ACJD remains controversial.^[20-22]

The use of HP and DB has been popularized because of their good to excellent results in ACJD treatment. Still, there is no consensus in the literature about which technique is superior.^[23,24] Our literature review for studies comparing DBs and HPs yielded ten meta-analyses/systematic reviews^[25-34] and many comparative studies.^[16,23,24,35-43] These comparative studies were mostly based on the arthroscopic DB technique. A few of them were based on the minimal invasive DB technique.^[23,40] Only two were directly about open reduction and fixation, as in this study.^[36,43]

The aim of this study is to compare open DB and HP techniques in the treatment of Rockwood Type III/V ACJDs in terms of clinical and radiological outcomes and to determine which method is superior.

MATERIALS AND METHODS

This retrospective comparative study was performed under the approval of our institution's ethical review board and was conducted in accordance with the Declaration of Helsinki. All patients gave their written consent before surgery and accepted that their medical data could be used for scientific research. Between June 2014 and February 2018, a consecutive series of 43 patients (39 men, 4 women; mean age 41.8 ± 17.4) underwent surgical treatment for acute Rockwood Type III/V (18/25 patients) ACJD in our Level I trauma center.

Patients with acute (≤ 3 weeks) Rockwood Type III (Athletes, active laborers, patients who had frequent overhead activities in their daily lives, and young active patients with high demands) or Type V ACJD (1), patients with age ≥ 18 (2), patients with mono-trauma (3), patients implanted with either a 3.5 mm locking compression HP (of various trademarks) or a DB device (ArthroSport double lift loop system, KC grup, Ankara, Turkey), (4) patients with a minimum follow-up of 12 months after surgery, and (5) were included in this study. Patient selection flow chart is represented in Figure 1.

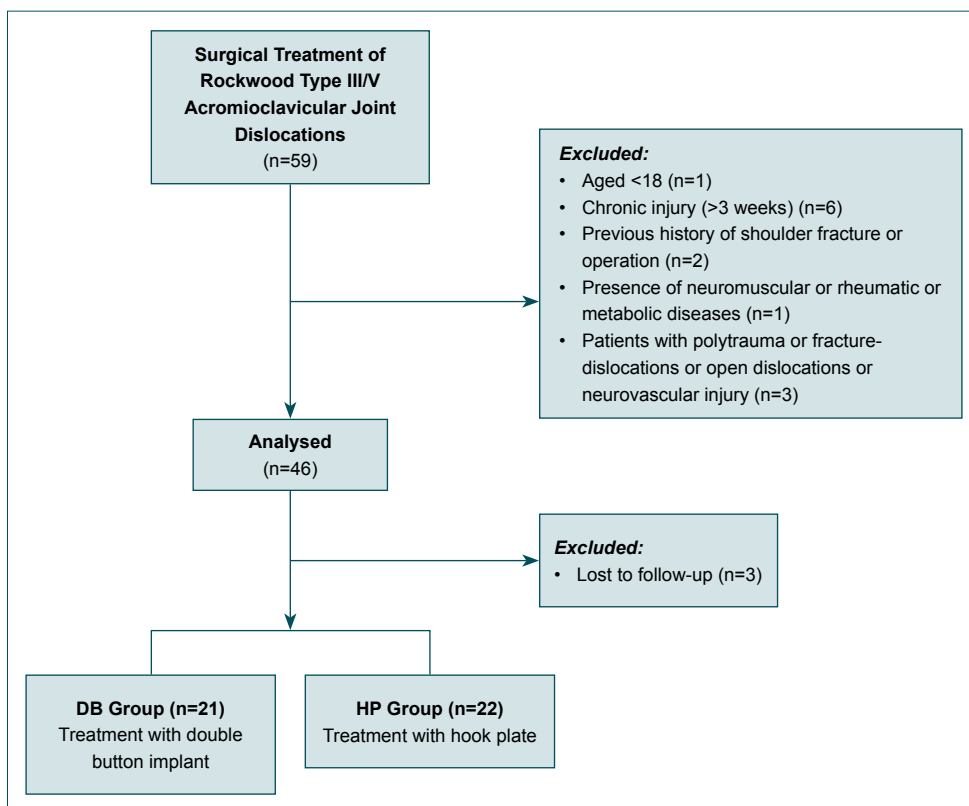


Figure 1. Patient selection flow chart.

The choice of each implant used during the study period was dependent on the availability of these devices at our university hospital during the interventions. Before April 2016, the DB implant was not available in our institution according to the rules of tender regulated by law. Thus, patients operated on between June 2014 and April 2016 were implanted with HPs. After April 2016, only the DB implant was used for the fixation of ACJDs, and HP was reserved for only distal clavicular fractures and clavicle fractures with dislocations. Thus, ACJD patients operated on between April 2016 and February 2018 were implanted with only DBs. Therefore, the decision regarding the choice of either DB or HP was not based on any patient or fracture characteristics.

Surgical Technique

All patients in both groups received antibiotic prophylaxis with a single dose of intravenous cefazolin before the operation, and no effort was made to directly repair the AC/CC ligaments. The reductions were held still by temporary fixation with AC K wires or a bone holding forceps.

HP

Under general anesthesia and fluoroscopic guidance in a beach chair position, a 5–7 cm long skin incision was made transversely along the clavicle axis, including the AC joint. AC joint was reduced. If the articular disk blocked the reduction, it was excised. Then the hook of the 3.5 mm plate is placed under the acromion as posteriorly as possible, and the body of the plate was fixed to the clavicle with screws. The deltotracheal fascia and the wound were closed in layers after rinse.

DB

The DB used for the current study's operations is a device with two titanium buttons (clavicular and coracoidal) joined by a continuous loop of #7 klothofiber (Fig. 2). Under general anesthesia and fluoroscopic guidance in a beach chair position, a 5 cm long vertical saber-cut incision was performed from 3 cm medial of the AC joint line to the coracoid. The upper surface of the clavicle and undersurface of the coracoid were prepared with the cautery. After AC joint reduction, a transclavicular-transcoracoidal guidewire was placed. Then, the guidewire was drilled with a 4 mm drill. The single bundle DB was inserted through bone tunnels with the help of a shuttle suture. The buttons under the acromion and over the clavicle were flipped. The traction sutures were pulled until the clavicular button locked. There was no need to tie the traction sutures over the clavicular button due to the self-locking lift-loop design. The wound was closed in layers after rinse.

Post-operative Management

For the HP patients, the shoulder was immobilized with a sling for 1 week. Limited shoulder motion (90° abduction and flexion) was permitted between the 2nd and 6th weeks.




Figure 2. Double-button device (ArtroSport double lift loop system, KC grup, Ankara, Turkey). The bottom button is the coracoidal button with the shuttle suture, whereas upper button is clavicular button with traction sutures.

Free range of motion (ROM) was allowed after the 6th week. Implant removal (IR) was advised at the end of 3rd month after index surgery. For the DB patients, the shoulder was protected in a sling for 3 weeks. In this period, only passive motion (45° abduction and flexion) was allowed. Between the 4th and 6th weeks, active-assisted motion exercises were performed. After the 6th week, a free ROM was allowed. Light resistance work was allowed after the 8th week, whereas heavy resistance work and sports were permitted after the 3rd month in both groups.

Data Evaluation

Main clinical characteristics of the patients included demographic and perioperative data: Age, sex, side, body mass index, mechanism of injury, Rockwood classification, type of anesthesia, and American Society of Anesthesiologists (ASA) classification, injury to surgery time (days), hospitalization time (days), operation time (minutes), fluoroscopy time (seconds), intraoperative blood loss (milliliters), return to work time (weeks), and HP removal time (weeks).

The constant score (CS) was performed to assess the functional outcomes at the post-operative 12th month. CS consists of four subscales: pain (15 points), activities of daily living (20 points), ROM (40 points), and strength (25 points). A higher score means a higher function of the shoulder.^[44] Visual analog scale (VAS) is a measure of pain intensity. VAS score varies from 0 to 10. The lower score represents less pain. Two independent observers evaluated the patients in the outpatient clinic at post-operative 1st, 6th, and 12th

months, and then annually. Operations were performed by senior orthopedic surgeons.

For radiological evaluation, Zanca view (Shoulder AP view with 10–15° cephalic tilt focused on AC joint) was used. CC distances (CCDs) were measured at the preoperative, early postoperative, and the latest follow-up visits. The CCD was defined as the vertical distance between the coracoid's uppermost border and the clavicle's inferior border. This distance was measured via a PACS viewer program with a radio dense object (which has a known diameter of 25 mm) used as a caliper.

Overcorrection was defined if the inferior border of the clavicle is below the inferior border of the acromion. In contrast, under correction is determined if the clavicle's inferior border is above the acromion's inferior border and the vertical distance between them is more than 2 mm on early postop-

erative radiographs. A reduction is defined anatomic if this distance is ≤ 2 mm. Early post-operative and latest follow-up radiographs were compared for the potential loss of reduction.

Complications were classified as technical and local. Technical complications were AC joint arthritis, subacromial osteolysis, malreduction (initial overcorrection and under correction), slight loss of reduction after IR, implant breakage, dislocation due to the coracoid cutout, and soft-tissue interposition under the coracoid (Figs. 3–6). Local complications were superficial infection and hypertrophic scar. IR and revision due to the dislocation were the reasons for reoperation.

Statistical Analysis

Descriptive statistical analysis was performed using SPSS 25.0 (SPSS Inc., IBM, NY, USA). Numerical variables were given as means, standard deviations, and categorical variables provided

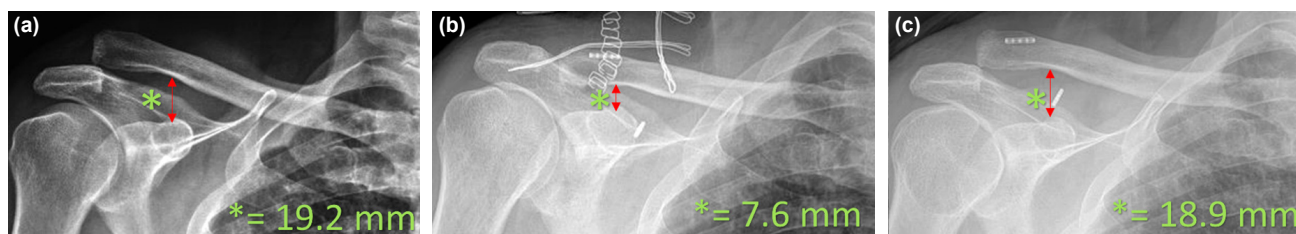


Figure 3. Measurement of the coracoclavicular distance (CCD) of a patient with Rockwood type V acromioclavicular joint dislocation on the pre-operative Zanca view (a). The CCD is the vertical distance between the coracoid's uppermost border and the inferior border of the clavicle. Note that there was a coracoidal tunnel/button malposition on the early post-operative Zanca view (b). This malposition caused a cutout of the coracoidal button at the third postoperative week (c) and led to a dislocation and a reoperation.

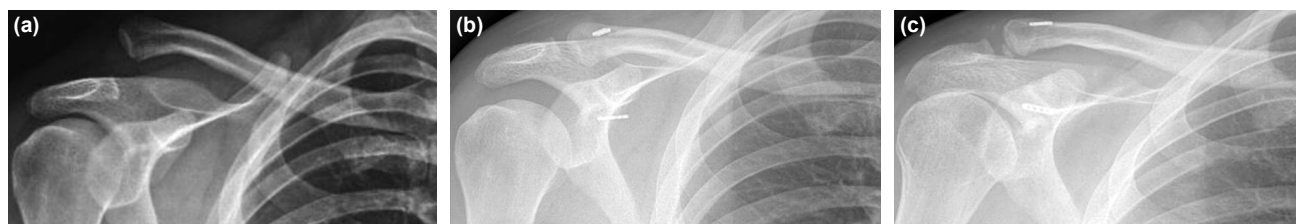

Figure 4. The pre-operative Zanca view of a patient with Rockwood type V acromioclavicular joint dislocation (a). Note that there was a soft tissue interposition between the coracoidal button and the coracoid on the early postoperative Zanca view (b). After the button's settlement under the coracoid, there was a slight loss of reduction (c).

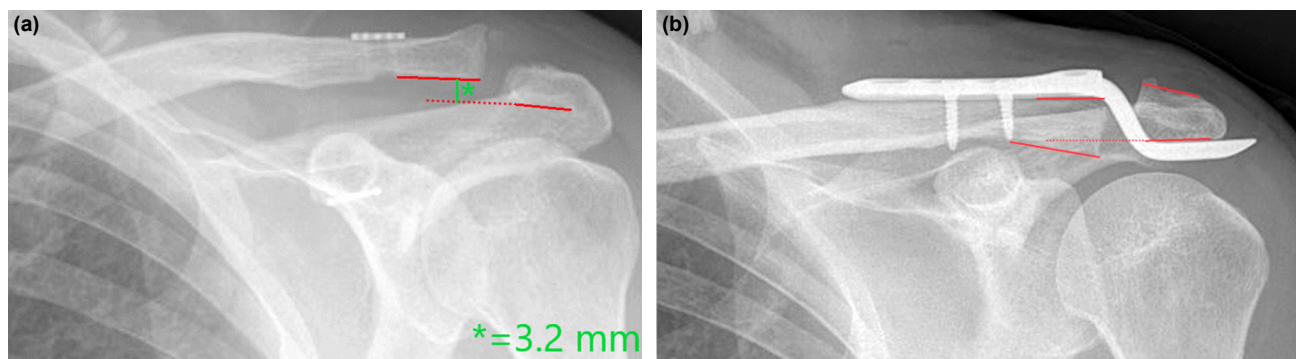


Figure 5. The early post-operative Zanca views of patients with under correction (a) and overcorrection (b). Overcorrection was defined if the inferior border of the clavicle is below the inferior border of the acromion. In contrast, under correction is determined if the clavicle's inferior border is above the acromion's inferior border and the vertical distance between them is more than 2 mm on the early post-operative radiographs.

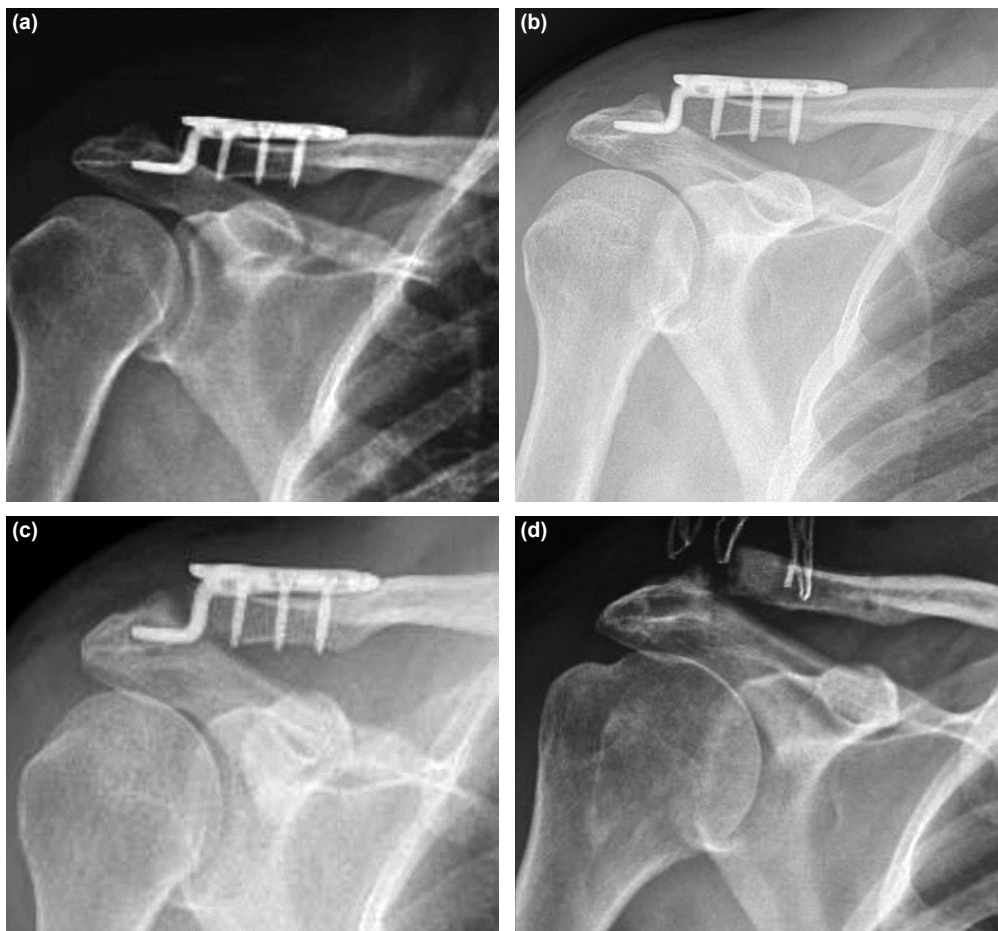


Figure 6. Early post-operative (a), 6th month (b), 9th month (c) and after implant removal (IR) (d) Zanca views of a patient first refused the IR offer, then requested IR himself at the 9th month due to persistent shoulder pain. Note that the subacromial osteolysis was slowly causing the plate's hook to cut through the acromion (intra-acromial migration) (b and c). After the IR, there was a slight loss of reduction, and the acromioclavicular joint arthritis became obvious (d).

as frequencies and percentages. Means were compared using student t-test or Mann–Whitney U test in accordance with the Shapiro–Wilk normality test. A Chi-square test (if the minimum expected count >5) or Fisher exact test (if the minimum expected count <5) was used to test differences between observed frequencies. The intra-class correlation coefficient (ICC), with the associated 95% confidence interval, was used to evaluate intra-observer and inter-observer agreement in the CCD measurements. Based on Landis and Koch's study,^[45] we defined agreement for ICC scores as 0–0.2, slight agreement; 0.21–0.40, fair; 0.41–0.60, moderate; 0.61–0.8, substantial; and >0.81 as perfect agreement. Accordingly, the inter-observer reliability (ICC: 0.992, 95% Confidence Interval [CI]: 0.858–0.997) and the intra-observer reliability (ICC: 0.999, 95% CI: 0.999–1.000) of CCD measurements were perfect. $P < 0.05$ was considered statistically significant.

RESULTS

The patients' main clinical characteristics, complications, reasons for reoperation, functional scores, and CCD measure-

ments are represented in Tables 1 and 2. Most of the main clinical characteristics (demographics, injury mechanisms, dislocation types, ASA types, anesthesia types, mean follow-up time, mean injury to surgery time, mean hospitalization time, and mean intraoperative blood loss) were similar between groups. The DB led to shorter fluoroscopy and operation times ($p < 0.01$, and $p < 0.01$), a shorter time to return to work ($p = 0.04$), lesser complication and reoperation rates ($p = 0.04$ and $p < 0.01$, respectively), a better functional result (CS) ($p = 0.03$) and a lesser post-operative pain (VAS) ($p = 0.01$). Pre-operative, early post-operative, and latest mean CCD measurements were similar between groups. The differences between mean CCDs of pre-operative and early post-operative periods were statistically significant in both DB ($p < 0.01$) and HP groups ($p < 0.01$). However, the increases of mean CCDs between early postoperative and latest periods were not statistically significant in the DB ($p = 0.33$) and HP groups ($p = 0.28$). Five patients (22.8%) in the HP group rejected IR advice because they were satisfied with their shoulder function. Interestingly, one of these patients that refuse IR had an implant failure (hook breakage). Most of the HP implants

Table 1. Main clinical characteristics of the patients

	Double-Button	Hook Plate	p-value	Test
Number of patients	21	22		
Mean age (years)	44.5±18	39.3±16.8	0.38	Mann-Whitney U
Mean follow-up (months)	20.6±8.3	20.7±6.8	0.82	Mann-Whitney U
Gender, n (%)			0.32	Chi-square
Male	20 (95.2)	19 (86.4)		
Female	1 (4.8)	3 (13.6)		
Side, n (%)			0.85	Chi-square
Right	13 (61.9)	13 (59.1)		
Left	8 (38.1)	9 (40.9)		
BMI (kg/m ²)	25.1±3.3	24.1±2.0	0.28	Mann-Whitney U
Mechanism of injury, n (%)			0.66	Chi-square
Simple fall	12 (57.1)	14 (63.6)		
Bicycle/motorcycle accident	9 (42.9)	8 (36.4)		
Rockwood classification, n (%)			0.63	Chi-square
Type 3	8 (38.1)	10 (45.5)		
Type 5	13 (61.9)	12 (54.5)		
ASA classification, n (%)			0.48	Chi-square
ASA 1	18 (85.7)	17 (77.3)		
ASA 2	3 (14.3)	5 (22.7)		
Type of anesthesia, n (%)				
General	21 (100)	22 (100)		
Mean injury to surgery time (days)	4.0±3.1	4.2 ±3.1	0.59	Mann-Whitney U
Mean hospitalization time (days)	1.2±0.5	1.3±0.7	0.96	Mann-Whitney U
Mean operation time (min)	47.3±5.3	55.2±3.0	<0.01	T-test
Mean fluoroscopy time (s)	12.4±0.7	20.2±2.1	<0.01	Mann-Whitney U
Mean intraoperative blood loss (ml)	49.8±6.8	52.0±4.8	0.07	Mann-Whitney U
Mean return to work time (weeks)	9.9±2.0	11.7±1.2	0.04	Mann-Whitney U
Hook plate removal time (weeks)	–	16.8±7.5		

BMI: Body mass index; ASA: American Society of Anesthesiologists.

were removed between the 3rd and 5th months. Three patients first refused the IR offer, and then requested IR themselves between 7th and 9th months due to persistent shoulder pain, and their implants were removed. They were satisfied after IR. All of the reoperations in the HP group (17 out of 22) were due to IR, whereas the DB group's only reoperation was caused by a coracoid cutout leading to redislocation. Coracoid tunnel malposition was the reason for this cutout. One patient in the DB group had a soft-tissue interposition under the coracoid. This situation improved over time as the button settled where it should have been. A slight loss of reduction was observed after this settlement.

DISCUSSION

The most important finding of this study is that DB is superior to HP in terms of complication and reoperation rates,

functional score (CS), pain (VAS), operation/fluoroscopy times, and time to return to work. We attribute these differences to first the HP technique being more susceptible to the development of complications that cause shoulder pain and movement impairment (AC joint arthritis and subacromial osteolysis), and second the need for a second surgery to remove the implant.

The meta-analysis of Wang et al.^[28] (consists of eight eligible studies) demonstrated that the DB technique had better outcomes (higher CS and lower VAS) than the HP technique as in this study. Both methods were found to have similar operation times, CCDs, complications, and reduction losses. Furthermore, they speculated that the arthroscopic DB technique might be superior to the open DB technique. Similarly, the results of the meta-analysis of Qi et al.^[30] (consists of 13

Table 2. Complications, reasons for reoperation, functional scores, and CCD measurements

Technical complications	Double-Button		Hook Plate		p-value	Test
	n	%	n	%		
ACJ arthritis	1	4.8	8	36.4	0.02	Fisher Exact
Subacromial osteolysis	–	–	7	31.9		
Malreduction	2	9.6	5	2.8		
Initial overcorrection	–	–	5	22.8		
Initial undercorrection	2	9.6	–	–		
Slight loss of reduction after implant removal	–	–	4	23.6		
Implant breakage	0	0	1	4.6		
Dislocation due to coracoid cutout	1	4.8	–	–		
Soft tissue interposition under the coracoid	1	4.8	–	–		
Local complications						
Superficial infection	1	4.8	1	4.6		
Hypertrophic scar	1	4.8	2	9.1		
Patients with at least one complication	5	23.8	12	54.6	0.04	Chi-square
Reoperation						
Implant removal	–	–	17	77.3		
Revision due to dislocation	1	4.8	–	–		
Total	1	4.8	17	77.3	<0.01	Chi-square
Functional scores						
Mean CS		92.1±3.4		88.3±4.2	0.03	Mann-Whitney U
Mean VAS score		0.8±1.0		1.5±1.0	0.01	Mann-Whitney U
CCD measurements						
Pre-operative (mm)		20.43±3.8		20.23±3.7	0.80	Mann-Whitney U
Early post-operative (mm)		8.05±1.4		7.05±1.9	0.19	Mann-Whitney U
Latest (mm)		8.57±2.0		7.68±1.9	0.48	Mann-Whitney U

ACJ: Acromioclavicular joint; CS: Constant score; VAS: Visual analog scale; CCD: Coracoclavicular distance.

eligible studies) showed that DB was preferential to HP due to better outcomes (higher CS and lower VAS) with similar reduction loss rate and CCD results. In a meta-analysis (consists of 36 eligible studies) by Arirachakaran et al.,^[33] LSF (tightrope, endobutton, synthetic ligament, or PDS sling) was found to have higher functional scores (CS) and lower post-operative pain compared to HP. However, the complication rates were also higher in the LSF group. In another meta-analysis by Arirachakaran et al.^[25] (consists of five eligible studies) reported that LSF had a better functional result (mean CS) but a higher mean operation time compared to HP. Mean VAS and complication rates were reported to be similar. Pan et al.^[29] stated in their meta-analysis (consists of four eligible studies) that both DB and HP procedures had effective functional outcomes. Still, DB was advantageous in terms of postoperative pain.

In contrast to these studies, Helfen et al.^[26] found no evidence in their meta-analysis (consist of three eligible stud-

ies) for a general superiority of any open or arthroscopic or minimal invasive techniques in the treatment of acute ACJDs, but there was a reported tendency for a better functional outcome (CS) after arthroscopic procedures. Jensen et al.^[27] had similar results with this study in their review and added that there was a higher degree of acceptance among patients for the arthroscopic and minimally invasive DB techniques. Besides, the systematic review of Lloyd et al.^[31] (consists of six eligible studies) reported no statistically significant differences between DB and HP in terms of complications, revisions, malreductions, post-operative pain scores, and functional outcomes. Similarly, there were no differences in loss of reduction, the complication rate, and the revision rate between AC reconstruction techniques in the meta-analysis of Gowd et al.^[32] (consists of 58 eligible studies).

The HP technique is a common treatment method for ACJDs due to the advantages of a simple procedure, reported good outcomes, and achieving reduction in both horizontal and

vertical planes.^[22,46,47] However, it has disadvantages such as shoulder pain and impingement, rotator cuff tears, limited shoulder motion, AC degeneration, subacromial osteolysis, superior migration of hook through the acromion, mandatory second (IR) operation (recommended at 3 months after the index surgery), redislocation/subluxation after IR, and material fatigue/breakage.^[16,20,21,48–51] The DB technique is increasingly used with either arthroscopically, minimal invasive, or open procedures.^[52] It has good to excellent outcomes with high fixation strength and no need for IR.^[53–56] This technique's most reported complications include infection, shoulder pain, coracoid/clavicle fracture, implant failure, loss of reduction, and CC calcification.^[57] In the literature, the rates of complications are up to 54.2% and 40% for DB and HP, respectively.^[36,41] Our complication rate of DB (23.8%) is within this limit. We attribute the high HP complication rate (54.6%) of this study to the rejection of IR by some of the patients, the mean IR time being longer than 3 months, and the detailed design of this study. Similar to our research, Moatshe et al.^[34] found that HP was associated with the highest complication rates among other AC and CC reconstruction techniques in their systematic review of 34 studies. The reoperation rates, excluding routine HP removal, are up to 31.8% and 42.3% for DB and HP, respectively.^[41] Our reoperation rates were within this limit. Malreduction was reported only in one study with rates of 40% and 36.3% for DB and HP, respectively. Our rates were within these limits. We think that DB patients tend to have under corrections because the fluoroscopy is not appropriately used to check the reduction of the AC joint. Direct visualization might be deceiving the surgeon about the adequacy of the reduction. In contrast, HP patients tend to have overcorrections due to the use of HPs with inadequate vertical heights. The reported CCDs after DB and HP surgeries vary between 7.5 mm and 23.8 mm.^[24,43] This high variation between studies was caused using both radiographic and ultrasonographic techniques for the measurement. To avoid this variation, expressing the measurements as a percentage by comparing them to the contralateral shoulder can facilitate the assessment. Our CCDs reported in this study are within these limits.

This study is one of few studies reporting the outcomes of the open DB technique compared to HP, which is thought to be the main strength of this study. Besides, our results were very detailed and given with a brief literature review comparing DB and HP techniques. The sample size is comparable to other comparative studies. The main limitations of this study are the retrospective setting, the use of various HPs, and the randomization based on the availability of the implants rather than a blinded protocol. One should bear in mind that prospective randomized controlled trials are essential to compare different implants.

Conclusion

DB was superior to HP in terms of complication and reoperation rates, functional score, post-operative pain, operation/

fluoroscopy times, and time to return to work. Mandatory IR was also an obvious disadvantage for the patients implanted with an HP. Open DB technique should be preferential to HP procedure.

Ethics Committee Approval: This study was approved by the Erzincan Binali Yildirim University Clinical Research Ethics Committee (Date: 30.03.2020, Decision No: 33216249-903.99-E.14477).

Peer-review: Internally peer-reviewed.

Authorship Contributions: Concept: F.Y., H.U., V.G., A.S., Y.O.K., R.K., Y.C.; Design: F.Y., H.U., V.G., A.S., Y.O.K., R.K., Y.C.; Supervision: F.Y., H.U., V.G., A.S., Y.O.K., R.K., Y.C.; Resource: F.Y., H.U., V.G., A.S., Y.O.K., R.K., Y.C.; Materials: F.Y., H.U., V.G., A.S., Y.O.K., R.K., Y.C.; Data: F.Y., H.U., V.G., A.S., Y.O.K., R.K., Y.C.; Analysis: F.Y., H.U., V.G., A.S., Y.O.K., R.K., Y.C.; Literature search: F.Y., H.U., V.G., A.S., Y.O.K., R.K., Y.C.; Writing: F.Y., H.U., V.G., A.S., Y.O.K., R.K., Y.C.; Critical revision: F.Y., H.U., V.G., A.S., Y.O.K., R.K., Y.C.

Conflict of Interest: None declared.

Financial Disclosure: The authors declared that this study has received no financial support.

REFERENCES

- Gorbaty JD, Hsu JE, Gee AO. Classifications in brief: Rockwood classification of acromioclavicular joint separations. *Clin Orthop Relat Res* 2017;475:283–7. [\[CrossRef\]](#)
- Li Q, Hsueh P, Chen Y. Coracoclavicular ligament reconstruction. *Medicine (Baltimore)* 2014;93:e193. [\[CrossRef\]](#)
- Rieser GR, Edwards K, Gould GC, Markert RJ, Goswami T, Rubino LJ. Distal-third clavicle fracture fixation: A biomechanical evaluation of fixation. *J Shoulder Elb Surg* 2013;22:848–55. [\[CrossRef\]](#)
- Oussedik S. Injuries to the clavicle and acromioclavicular joint. *Br J Hosp Med* 2007;68:M68–70. [\[CrossRef\]](#)
- Willimon SC, Gaskill TR, Millett PJ. Acromioclavicular joint injuries: Anatomy, diagnosis, and treatment. *Phys Sportsmed* 2011;39:116–22.
- Chillemi C, Franceschini V, Dei Giudici L, Alibardi A, Santone FS, Al-day LJ, et al. Epidemiology of isolated acromioclavicular joint dislocation. *Emerg Med Int* 2013;2013:1–5. [\[CrossRef\]](#)
- Cho CH, Hwang I, Seo JS, Choi CH, Ko SH, Park HB, et al. Reliability of the classification and treatment of dislocations of the acromioclavicular joint. *J Shoulder Elb Surg* 2014;23:665–70. [\[CrossRef\]](#)
- Rockwood CJ, Green D. Injuries to the acromioclavicular joint. In: Rockwood CJ, editor. *Fractures in Adults*. 1st ed. Philadelphia, PA: Lippincott; 1984. p. 860–910.
- Tauber M. Management of acute acromioclavicular joint dislocations: Current concepts. *Arch Orthop Trauma Surg* 2013;133:985–95. [\[CrossRef\]](#)
- Smith TO, Chester R, Pearse EO, Hing CB. Operative versus non-operative management following Rockwood grade III acromioclavicular separation: A meta-analysis of the current evidence base. *J Orthop Traumatol* 2011;12:19–27. [\[CrossRef\]](#)
- Ponce BA, Millett PJ, Warner JJ. Acromioclavicular joint instability-reconstruction indications and techniques. *Oper Tech Sports Med* 2004;12:35–42. [\[CrossRef\]](#)
- Cote MP, Wojcik KE, Gomlinski G, Mazzocca AD. Rehabilitation of

- acromioclavicular joint separations: Operative and nonoperative considerations. *Clin Sports Med* 2010;29:213–28. [\[CrossRef\]](#)
13. Horst K, Dienstknecht T, Andruszkow H, Gradl G, Kobbe P, Pape HC. Radiographic changes in the operative treatment of acute acromioclavicular joint dislocation-tight rope technique vs. K-wire fixation. *Polish J Radiol* 2013;78:15–20. [\[CrossRef\]](#)
 14. Esenyel CZ, Öztürk K, Bülbül M, Ayanoglu S, Ceylan HH. Coracoclavicular ligament repair and screw fixation in acromioclavicular dislocations. *Acta Orthop Traumatol Turc* 2010;44:194–8. [\[CrossRef\]](#)
 15. Mares O, Luneau S, Staquet V, Bertrand E, Bousquet PJ, Maynou C. Acute grade III and IV acromioclavicular dislocations: Outcomes and pitfalls of reconstruction procedures using a synthetic ligament. *Orthop Traumatol Surg Res* 2010;96:721–6. [\[CrossRef\]](#)
 16. Eschler A, Gradl G, Gierer P, Mitlmeier T, Beck M. Hook plate fixation for acromioclavicular joint separations restores coracoclavicular distance more accurately than PDS augmentation, however presents with a high rate of acromial osteolysis. *Arch Orthop Trauma Surg* 2012;132:33–9.
 17. Guttmann D, Paksima NE, Zuckerman JD. Complications of treatment of complete acromioclavicular joint dislocations. *Instr Course Lect* 2000;49:407–13. [\[CrossRef\]](#)
 18. Kienast B, Thietje R, Queitsch C, Gille J, Schulz AP, Meiners J. Mid-term results after operative treatment of Rockwood Grade III-V acromioclavicular joint dislocations with an AC-hook-plate. *Eur J Med Res* 2011;16:52–6. [\[CrossRef\]](#)
 19. Morrison DS, Lemos MJ. Acromioclavicular separation: Reconstruction using synthetic loop augmentation. *Am J Sports Med* 1995;23:105–10.
 20. Bannister GC, Wallace WA, Stableforth PG, Hutson MA. The management of acute acromioclavicular dislocation. A randomised prospective controlled trial. *J Bone Joint Surg Ser B* 1989;71:848–50. [\[CrossRef\]](#)
 21. Hoffer CE, Karas SG. Transacromial erosion of a locked subacromial hook plate: Case report and review of literature. *J Shoulder Elb Surg* 2010;19:e12–9. [\[CrossRef\]](#)
 22. Johansen JA, Grutter PW, McFarland EG, Petersen SA. Acromioclavicular joint injuries: Indications for treatment and treatment options. *J Shoulder Elb Surg* 2011;20:570–82. [\[CrossRef\]](#)
 23. Metzclaff S, Rosslenbroich S, Forkel PH, Schliemann B, Arshad H, Raschke M, et al. Surgical treatment of acute acromioclavicular joint dislocations: Hook plate versus minimally invasive reconstruction. *Knee Surgery, Sport Traumatol Arthrosc* 2016;24:1972–8. [\[CrossRef\]](#)
 24. Jensen G, Katthagen JC, Alvarado LE, Lill H, Voigt C. Has the arthroscopically assisted reduction of acute AC joint separations with the double tight-rope technique advantages over the clavicular hook plate fixation? *Knee Surg Sport Traumatol Arthrosc* 2014;22:422–30. [\[CrossRef\]](#)
 25. Arirachakaran A, Boonard M, Piyapittayanun P, Phiphobmongkol V, Chaijenkij K, Kongtharvonkul J. Comparison of surgical outcomes between fixation with hook plate and loop suspensory fixation for acute unstable acromioclavicular joint dislocation: A systematic review and meta-analysis. *Eur J Orthop Surg Traumatol* 2016;26:565–74. [\[CrossRef\]](#)
 26. Helfen T, Siebenbürger G, Ockert B, Haasters F. Therapie der akuten AC-Gelenk-Instabilität: Eine metaanalyse arthroskopischer/minimal-invasiver vs. offener Verfahren. *Unfallchirurg* 2015;118:415–26. [\[CrossRef\]](#)
 27. Jensen G, Ellwein A, Voigt C, Katthagen JC, Lill H. Injuries of the acromioclavicular joint: Hook plate versus arthroscopy. *Unfallchirurg* 2015;118:1041–55. [\[CrossRef\]](#)
 28. Wang C, Meng JH, Zhang YW, Shi MM. Suture button versus hook plate for acute unstable acromioclavicular joint dislocation: A meta-analysis. *Am J Sports Med* 2020;48:1023–30. [\[CrossRef\]](#)
 29. Pan X, Yan LR, Gang LM, Guang ZD. TightRope vs clavicular hook plate for rockwood III-V acromioclavicular dislocations: A meta-analysis. *Orthop Surg* 2020;12:1045–52. [\[CrossRef\]](#)
 30. Qi W, Xu Y, Yan Z, Zhan J, Lin J, Pan X, et al. The tight-rope technique versus clavicular hook plate for treatment of acute acromioclavicular joint dislocation: A systematic review and meta-analysis. *J Invest Surg* 2021;34:20–9. [\[CrossRef\]](#)
 31. Lloyd AJ, Hurley ET, Davey MS, Pauzenberger L, Mullet H. Arthroscopic suture-button versus hook-plate fixation for acromioclavicular joint injuries-a systematic review of comparative studies. *Arthrosc Sport Med Rehabil* 2020;2:e671–6. [\[CrossRef\]](#)
 32. Gowd AK, Liu JN, Cabarcas BC, Cvetanovich GL, Garcia GH, Manderle BJ, et al. Current concepts in the operative management of acromioclavicular dislocations: A systematic review and meta-analysis of operative techniques. *Am J Sports Med* 2019;47:2745–58. [\[CrossRef\]](#)
 33. Arirachakaran A, Boonard M, Piyapittayanun P, Kanchanatawan W, Chaijenkij K, Prommahachai A, et al. Post-operative outcomes and complications of suspensory loop fixation device versus hook plate in acute unstable acromioclavicular joint dislocation: A systematic review and meta-analysis. *J Orthop Traumatol* 2017;18:293–304. [\[CrossRef\]](#)
 34. Moatshe G, Kruckeberg BM, Chahla J, Godin JA, Cinque ME, Provencher MT, et al. Acromioclavicular and coracoclavicular ligament reconstruction for acromioclavicular joint instability: A systematic review of clinical and radiographic outcomes. *Arthrosc J Arthrosc Relat Surg* 2018;34:1979–95.e8. [\[CrossRef\]](#)
 35. Andreani L, Bonicoli E, Parchi P, Piolanti N, Michele L. Acromio-clavicular repair using two different techniques. *Eur J Orthop Surg Traumatol* 2014;24:237–42. [\[CrossRef\]](#)
 36. Sokkar S, Radwan M, Toreih A. Hook plate versus tightrope for acute grade III acromioclavicular dislocation. *Egypt Orthop J* 2016;51:137.
 37. Yoon JP, Lee BJ, Nam SJ, Chung SW, Jeong WJ, Min WK, et al. Comparison of results between hook plate fixation and ligament reconstruction for acute unstable acromioclavicular joint dislocation. *CiOS Clin Orthop Surg* 2015;7:97–103. [\[CrossRef\]](#)
 38. Cai L, Wang T, Lu D, Hu W, Hong J, Chen H. Comparison of the tight rope technique and clavicular hook plate for the treatment of rockwood type III acromioclavicular joint dislocation. *J Invest Surg* 2018;31:226–33. [\[CrossRef\]](#)
 39. Natera-Cisneros L, Sarasquete-Reiriz J, Escolà-Benet A, Rodríguez-Miralles J. Acute high-grade acromioclavicular joint injuries treatment: Arthroscopic non-rigid coracoclavicular fixation provides better quality of life outcomes than hook plate ORIF. *Orthop Traumatol Surg Res* 2016;102:31–9. [\[CrossRef\]](#)
 40. Bin Abd Razak HR, Yeo EMN, Yeo W, Lie TTD. Short-term outcomes of arthroscopic TightRope® fixation are better than hook plate fixation in acute unstable acromioclavicular joint dislocations. *Eur J Orthop Surg Traumatol* 2018;28:869–75. [\[CrossRef\]](#)
 41. Athar MS, Ashwood N, Arealis G, Hamlet M, Salt E. Acromioclavicular joint disruptions: A comparison of two surgical approaches 'hook' and 'rope.' *J Orthop Surg* 2018;26. [\[CrossRef\]](#)
 42. Läderrmann A, Gueorguiev B, Stimec B, Fasel J, Rothstock S, Hoffmeyer P. Acromioclavicular joint reconstruction: A comparative biomechanical study of three techniques. *J Shoulder Elb Surg* 2013;22:171–8. [\[CrossRef\]](#)
 43. Zhang J, Ying Z, Wang Y. Surgery for acromioclavicular dislocation: Factors affecting functional recovery. *Am Surg* 2017;83:1427–32. [\[CrossRef\]](#)
 44. Çelik D. Turkish version of the modified Constant-Murley score and standardized test protocol: Reliability and validity. *Acta Orthop Traumatol Turc* 2016;50:69–75. [\[CrossRef\]](#)
 45. Landis JR, Koch GG. The measurement of observer agreement for categorical data. *Biometrics* 1977;33:159. [\[CrossRef\]](#)
 46. Sim E, Schwarz N, Hocker K, Berzlanovich A. Repair of complete ac-

- romioclavicular separations using the acromioclavicular-hook plate. Clin Orthop Relat Res 1995;134–42. [CrossRef]
47. Simovitch R, Sanders B, Ozbaydar M, Lavery K, Warner JJP. Acromioclavicular joint injuries: Diagnosis and management. J Am Acad Orthop Surg 2009;17:207–19. [CrossRef]
48. Lin HY, Wong PK, Ho WP, Chuang TY, Liao YS, Wong CC. Clavicular hook plate may induce subacromial shoulder impingement and rotator cuff lesion-dynamic sonographic evaluation. J Orthop Surg Res 2014;9:6. [CrossRef]
49. Ejam S, Lind T, Falkenberg B. Surgical treatment of acute and chronic acromioclavicular dislocation Tossy type III and V using the hook plate. Acta Orthop Belg 2008;74:441–5.
50. Tiren D, van Bommel AJ, Swank DJ, van der Linden FM. Hook plate fixation of acute displaced lateral clavicle fractures: Mid-term results and a brief literature overview. J Orthop Surg Res 2012;7:2. [CrossRef]
51. Chen CH, Dong QR, Zhou RK, Zhen HQ, Jiao YJ. Effects of hook plate on shoulder function after treatment of acromioclavicular joint dislocation. Int J Clin Exp Med 2014;7:2564–70.
52. Defoort S, VerBorgt O. Functional and radiological outcome after arthroscopic and open acromioclavicular stabilization using a double-button fixation system. Acta Orthop Belg 2010;76:585–91.
53. Liu X, Huangfu X, Zhao J. Arthroscopic treatment of acute acromioclavicular joint dislocation by cofracoclavicular ligament augmentation. Knee Surg Sport Traumatol Arthrosc 2015;23:1460–6. [CrossRef]
54. Murena L, Vulcano E, Ratti C, Ceconello L, Rolla PR, Surace MF. Arthroscopic treatment of acute acromioclavicular joint dislocation with double flip button. Knee Surgery, Sport Traumatol Arthrosc 2009;17:1511–5. [CrossRef]
55. Petersen W, Wellmann M, Rosslenbroich S, Zantop T. Minimally invasive acromioclavicular joint reconstruction. (MINAR). Oper Orthop Traumatol 2010;22:52–61. [CrossRef]
56. Scheibel M, Dröschel S, Gerhardt C, Kraus N. Arthroscopically assisted stabilization of acute high-grade acromioclavicular joint separations. Am J Sports Med 2011;39:1507–16. [CrossRef]
57. Nelson A, Woodmass J, Esposito J, Nelson AA, Boorman RS, Thornton GM, et al. Complications following arthroscopic fixation of acromioclavicular separations: A systematic review of the literature. Open Access J Sport Med 2015;6:97. [CrossRef]

ORJİNAL ÇALIŞMA - ÖZ

Akut Rockwood Tip III/V akromiyoklaviküler çıkıklarının tedavisinde açık çift düğme tekniği kancalı plaktan üstündür

Dr. Furkan Yapici,¹ Dr. Hanifi Uçpunar,¹ Dr. Volkan Gur,¹ Dr. Ahmet Sevensan,² Dr. Yusuf Onur Kizilay,³ Dr. Resit Karakose,¹ Dr. Yalkın Camurcu³

¹Erzincan Üniversitesi Tıp Fakültesi, Ortopedi ve Travmatoloji Anabilim Dalı, Erzincan

²MS Baltalimanı Kemik ve Eklem Hastalıkları Eğitim ve Araştırma Hastanesi, Ortopedi ve Travmatoloji Kliniği, İstanbul

³Atlas Üniversitesi Tıp Fakültesi, Ortopedi ve Travmatoloji Anabilim Dalı, İstanbul

AMAÇ: Bu çalışmanın amacı, akromiyoklaviküler eklem dislokasyonu (AKED) tedavisinde açık çift düğme (ÇD) ve kancalı plak (KP) tekniklerini klinik ve radyolojik sonuçlar açısından karşılaştırmak ve hangi yöntemin daha üstün olduğunu belirlemektir.

GEREÇ VE YÖNTEM: Bu geriye dönük karşılaştırmalı çalışma, Haziran 2014 ile Şubat 2018 arasında bu implanterden biriyle (22 KP ve 21 ÇD hastası) tedavi edilen AKED hastalarını (Rockwood tip III/V) içermektedir.

BULGULAR: Çalışmaya yaş ortalaması 41.8±17.4 yıl olan toplam 43 hasta (39 erkek, 4 kadın) katılmıştır. Ortalama takip süresi 20.6±7.5 aydır. ÇD grubunda ortalama floroskopi, ameliyat ve işe dönüş süreleri daha kısadır. Sırasıyla ÇD ve KP grupları için komplikasyon oranları %23.8 ve %54.6, yeniden ameliyat oranları (zorunlu implant çıkarımı dahil) %4.8 ve %77.3, ortalama Constant skorları 92.1±3.4 ve 88.3±4.2, ortalama Görsel Analog skala puanları 0.8±1.0 ve 1.5±1.0 idi. İmplant çıkarımı, KP grubundaki tüm reoperasyonların ana nedeniydi. Oysa ÇD grubunun tek reoperasyonu, yeniden dislokasyona neden olan ve tünel malpozisyonundan dolayı gelişen bir korakoid sınırlamasından kaynaklandı. KP grubunda akromiyoklaviküler eklem artritisi (%36.4) ve subakromiyal osteoliz (%31.9) sık görüldü. ÇD grubunda en sık görülen komplikasyon malredüksiyonu (yetersiz korreksiyon) (%9.6).

TARTIŞMA: ÇD fonksiyonel sonuç, ameliyat sonrası ağrı, komplikasyon ve reoperasyon oranları, operasyon ve floroskopi süreleri ve işe dönme süresinde KP'den üstündür. Ayrıca KP hastalarının çoğunda implant çıkarımı nedeni reoperasyona ihtiyaç duyulmuştur. Bu nedenle, açık ÇD tekniği, KP prosedürüne tercih edilmelidir.

Anahtar sözcükler: Akromiyoklaviküler eklem dislokasyonu; ameliyat sonrası komplikasyonlar; asansörlü loop sistem; çift düğme; endobutton; kancalı plak; Rockwood sınıflaması; sütür düğme; tedavi sonuçları; tightrope.

Ulus Travma Acil Cerrahi Derg 2022;28(6):839-848 doi: 10.14744/tjtes.2021.45985